

Air Ambulance Inter-Hospital ECMO Retrieval of H1N1 Associated ARDS Patient First of Its Kind Case Reported in India

Gautam Rawal^{1*}, Raj Kumar², Sankalp Yadav³, Sujana R⁴

¹Associate Consultant, Respiratory Intensive Care, Max Super Specialty Hospital, Saket, New Delhi, India

²Senior Consultant and Incharge, Respiratory Intensive Care, Max Super Specialty Hospital, Saket, New Delhi, India

³General Duty Medical Officer-II, Department of Medicine & TB, Chest Clinic Moti Nagar, North Delhi Municipal Corporation, New Delhi, India

⁴Infection Control Unit, Max Super Specialty Hospital, Saket, New Delhi, India

*Address for Correspondence: Dr. Gautam Rawal, Associate Consultant, Respiratory Intensive Care, Max Super Specialty Hospital, Flat No. 417, Dhruva Apartments, Patparganj, Delhi, Pin-110092, India

Received: 06 Dec 2017/Revised: 25 Jan 2018/Accepted: 27 Feb 2018

ABSTRACT- Extracorporeal membrane oxygenation (ECMO) is a revolutionary life-saving technology for patients with severe but potentially reversible pulmonary or cardiac failure or for patients in need of a bridge to transplantation. In the Indian scenario, the facility of ECMO is limited to a few specialized healthcare centers having the expert personnel and the equipment for this technology. However, critically unwell patients with respiratory and/or cardiac failure are managed by all the healthcare facilities throughout the country. This has led to the development of mobile ECMO team which carries necessary equipment for initiation of ECMO at the referral center and also retrieval of the patient on ECMO. We presented, the case of a patient with H1N1 influenza associated severe ARDS who was retrieved via air-medical transport (fixed-wing aircraft) on ECMO by the mobile ECMO team of our center. In the present case, the patient was cannulated and ECMO was initiated at the referral hospital. This allowed a safe transfer of this patient with severe refractory hypoxemia to ECMO centre. The long or short-distance inter-hospital transport of critical patients with respiratory and/or cardiac failure is feasible and safer on ECMO as compared to the conventional methods of transport. The mobile ECMO teams have made this technology available to all even when the admitting hospital doesn't have this facility and expertise. To the author's knowledge, this was the first case reported in India of air-medical retrieval of a patient on ECMO.

Key-words- Acute respiratory distress syndrome (ARDS), Air ambulance, Extra corporeal membrane oxygenation (ECMO), H1N1 influenza (Swine flu), Hypoxia, Inter hospital transport

INTRODUCTION

Extra Corporeal Membrane Oxygenation (ECMO) has seen a remarkable recognition and evolution in its use in the last decade. ECMO has emerged as an invaluable tool in the hands of intensive care physicians in the management of patients with severe pulmonary and/or cardiac dysfunction refractory to conventional management ^[1], especially in patients with severe acute respiratory distress syndrome (ARDS). Though it is not a treatment modality in itself, it serves as a crucial bridge to therapy in a critical patient, bargaining time for the treatment or the management to be effective.

In India, ECMO is available only in few specialized centers, however, the patients with refractory respiratory

or heart failure are managed almost in all intensive care centers throughout the country where this technology is not feasible or available. Transporting a critical unwell patient to an ECMO center by the conventional methods can be life threatening and may cause fatality. This has led to the development of mobile ECMO team (intensivist, anesthetist, or surgeon along with intensive care nurse and perfusionist) by the few, out of the many, ECMO centers in India, including our center in Max Super Specialty Hospital, Saket, New Delhi ^[2]. Our ECMO services were established in 2013. The team carries necessary equipment for initiation of ECMO at a referral center. After the assessment, a final call is taken by the team if the patient can be transported on conventional therapies or needs ECMO retrieval. The presented case emphasizes the feasibility and safety of the inter-hospital transport of the patient on ECMO.

CASE PRESENTATION

A 51 year old obese lady (body mass index 31 Kg/m²) with a background of hypertension was admitted to Medical Intensive Care Unit (ICU), in the month of July 2016, of Max Hospital, Dehradun, Uttarakhand, India (A

Access this article online

Quick Response Code	Website: www.ijlssr.com
	 DOI: 10.21276/ijlssr.2018.4.2.5

Hilly Terrain), with bilateral pneumonia and acute hypoxemic respiratory failure. She was well until six days prior to hospital admission when she developed fever, cough and progressively increasing breathing difficulty.

On admission to medical ICU, she was in a state of severe respiratory distress with tachypnea, SpO₂ of 68% on room air and maintaining 89% on oxygen@10 liters/minute. Her pulse rate was 120/min, with blood pressure of 80/60 mmHg. She had bilateral crepitations in chest and rest of the systemic examination was unremarkable, with chest X-ray (CXR) showing bilateral non-homogenous infiltrates involving all the four quadrants of the lung. Septic screening (all cultures) including H1N1 influenza RT-PCR was sent, and she was empirically started on Piperacillin + Tazobactam, Clarithromycin, and Oseltamivir, along with vasopressor (norepinephrine) and supportive care. She was put on non invasive ventilatory support, but she continued to deteriorate and required endotracheal intubation and ventilation. Her SpO₂ remained low at around 81–85% despite FiO₂ of 1.0 and positive end expiratory pressure (PEEP) up to 14 cm H₂O, with arterial blood gas showing PaO₂/FiO₂ 85, pH 7.30, PaCO₂ 50mmHg suggesting severe ARDS with a Murray score of 3.5 and dynamic lung compliance of 15ml/cm H₂O. In view of refractory hypoxemia, she was put on prone position ventilation, which initially improved SpO₂ to 92%, but over the next few hours, her SpO₂ again dropped to 82%. ECMO was offered as a possible rescue and therapeutic option, and a reference was sent to our team for possible transfer to our ECMO center at Max Super Specialty Hospital, Saket, New Delhi, India.

ECMO team was mobilized within one hour of the call and was decided for air-medical retrieval considering the distance, traffic conditions, the hilly terrain of the referring hospital and the weather. The mobile ECMO team reached the reference hospital within about three hours of generating the call. After clinical re-assessment, it was decided to proceed with ECMO retrieval. Venovenous ECMO was installed bedside with 28 F access cannulae in the right femoral vein and 21 F return cannulae in the right internal jugular vein via the percutaneous approach by the team of intensivist and cardio-thoracic surgeon (Fig. 1). The procedure was completed without any complications. ECMO was initiated with settings of flow rate 60ml/kg/min, speed 3000 rotations/minute, sweep 5 litres/minute, fraction of delivered oxygen of 100% and rest lung ventilation with PEEP 10 cm H₂O and peak pressure 25 cm H₂O. On ECMO support, her SpO₂ improved to 98%. She was transported via road-ambulance on ECMO support to the airport, then in fixed wing airplane (about 45 minutes journey) and then again in road ambulance to our hospital. A total of about 300 km distance was covered within a time of 11 hours (including the quick assessment of the patient, cannulation and initiation of ECMO at the referral hospital). There were no complications during transport. The patient was admitted to ECMO ICU at our hospital and continued with the rest lung ventilation. Laboratory investigations were unremarkable except bronchoalveolar lavage and nasopharyngeal swab for

H1N1 influenza came positive. She showed good initial recovery with hemodynamic improvement and also improvement in lung compliance. Unfortunately, she developed secondary bacterial infection with septic shock and multi-organ dysfunction, on day 8 of ECMO initiation. Her antibiotics were escalated to Meropenem and Colistin. However, she continued to deteriorate and started requiring high dose of vasopressors to support her blood pressure and renal replacement support for acute renal failure and metabolic acidosis. Regretfully, despite all efforts and support she did not survive and expired on day 12 of ECMO. Informed consent was obtained for using the clinical images and the details of the case.

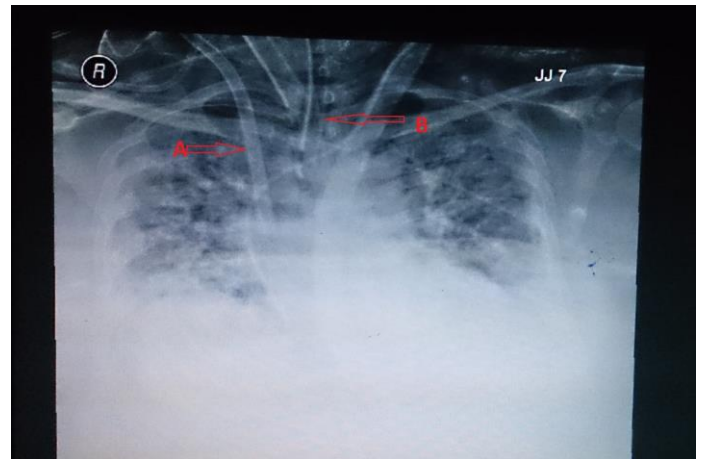


Fig. 1: Chest X-ray showing B/L infiltrates involving all the four quadrants of the lungs; **A**-ECMO cannula in Right IJV; **B**-Endotracheal tube in situ

DISCUSSION

The development of severe ARDS is a dreaded complication of H1N1 novel Influenza A viral infection. These patients with ARDS who do not respond positively with the conventional treatment (prone ventilation, protective lung ventilation using high PEEP and low tidal volume of 6ml/kg), are candidates who can be supported by ECMO, which prevents further organ damage due to hypoxia and acidosis and give sufficient time for the treatment to have an effect^[3]. The technology of ECMO is ever-evolving and needs the expertise of the healthcare staff for its effective and uncomplicated use. The scarcity of healthcare personnel with ECMO experience and the cost of this technology limit its use in India to a few major healthcare facilities in the metropolitan cities. The transport of these critical patients with ARDS to a specialized ECMO center becomes a necessity when the patient fails to improve with the conventional treatment modalities and the cause is potentially reversible. Occasionally, the patient may be critically unstable to travel by conventional transport and requires the ECMO to be initiated at the local hospital and then transfer. In our case, the patient had H1N1 associated ARDS who did not show any signs of improvement and remained hypotensive and hypoxic for more than 48 hours of using the optimum conventional management with ventilator. Transport of a patient with ongoing ECMO although remains a challenge, but has proved to be the only option

in some cases which can increase the patient survival chances by stabilizing the cardio respiratory failure. The published literature shows various complications while transporting a patient on ECMO including bleeding, occlusion or breakages of the circuit, failure of the pump, technical or mechanical complication of the transport vehicle, etc. [4-9]. In our case, there was no patient complication during transport, which was possible due to the optimization of the clinical parameters by the multi-disciplined and experienced ECMO retrieval team which clinically evaluated the patient and successfully initiated the patient on ECMO at the peripheral hospital. Unfortunately, the patient could not survive.

Extracorporeal Life Support Organization (ELSO) published guidelines for transport of patients on ECMO via the three modes of transport (ground ambulance, helicopter and the fixed-wing aircraft) which can be chosen depending upon the distance, weather conditions, and the availability (Table 1) [6,10].

Table 1: Properties of ground ambulance, helicopter, and fixed-wing aircraft (from ELSO guidelines)

Features	Ground ambulance	Helicopter	Fixed-wing aircraft
Space for team and equipment	Sufficient (4–5 team members)	More limited (3–5 team members)	Variable (≥4 team members)
Noise	Relatively little	Very loud	Loud
Distance for reasonable transport times	Up to 400 km (250–300 miles)	Up to 650 km (300–400 miles)	Any distance
Weight limitations	Unlimited	Limited (impacted by distance and weather)	Variable (depending on aircraft and conditions)
Loading and securing equipment and ECMO circuit/patient	Relatively easy	Relatively easy	Variable (depending on equipment and aircraft model)
Cost	++	+++	++++


CONCLUSIONS

The ECMO technology has emerged as a savior in patients with severe ARDS with reversible cause. The advancement of ECMO has led to the production of smaller equipment, which can be easily transported but still require the expertise and facility which is available in the specialized center. The authors emphasize the development of a mobile ECMO unit in these advance centers, who can evaluate and initiate ECMO at the referral hospital and then help in transport of the patient with reduced complications. The air medical transport has made it feasible for transport across long distances.

REFERENCES

- [1] Rawal G, Kumar R, Yadav S. ECMO Rescue Therapy in Diffuse Alveolar Haemorrhage: A Case Report with Review of Literature. *J. Clin. Diagn. Res.*, 2016; 10(6): OD10-11.
- [2] Kumar R, Verma D. Inter-hospital transport of severe acute respiratory distress syndrome on extracorporeal membrane oxygenation: Extracorporeal membrane oxygenation retrieval. *Lung India*, 2016; 33: 465-67.
- [3] Rawal G, Yadav S, Kumar R. Acute respiratory distress syndrome: An update and review. *J. Translational Internal Med.*, 2016. doi: 10.1515/jtim-2016-0012.
- [4] Haneya A, Philipp A, Foltan M, et al. Extracorporeal circulatory systems in the interhospital transfer of critically ill patients: experience of a single institution. *Ann. Saudi Med.*, 2009; 29(2): 110-14.
- [5] Lucchini A, De Felippis C, Elli S, et al. Mobile ECMO team for inter-hospital transportation of patients with ARDS: a retrospective case series. *Heart, Lung Vessels*, 2014; 6(4): 262-73.
- [6] Broman LM, Frenckner B. Transportation of Critically Ill Patients on Extracorporeal Membrane Oxygenation. *Frontiers in Pediatrics*, 2016; 4(63): 1-6.
- [7] Broman LM, Holzgraefe B, Palmér K, Frenckner B. The Stockholm experience: interhospital transports on extracorporeal membrane oxygenation. *Crit. Care*, 2015; 19(278): 1-6.
- [8] Isgrò S, Patroniti N, Bombino M, Marcolin R, Zanella A, et al. Extracorporeal membrane oxygenation for interhospital transfer of severe acute respiratory distress syndrome patients: 5-year experience. *Int. J. Artif. Organs.*, 2011; 34: 1052-60.
- [9] Ciapetti M, Cianchi G, Zagli G, Greco C, Pasquini A, et al. Feasibility of inter-hospital transportation using extracorporeal membrane oxygenation (ECMO) support of patients affected by severe swine-flu (H1N1) related ARDS. *Scandinavian J. Trauma, Resuscitation Emergency Med.*, 2011; 19(32): 2-6.
- [10] ELSO. Guidelines for ECMO Transport Ann Arbor: ELSO. Available from: <http://www.elseo.org/Resources/Guidelines.aspx>, 2015.

International Journal of Life Sciences Scientific Research (IJLSSR) Open Access Policy
 Authors/Contributors are responsible for originality, contents, correct references, and ethical issues.
 IJLSSR publishes all articles under Creative Commons Attribution- Non-Commercial 4.0 International License (CC BY-NC).
<https://creativecommons.org/licenses/by-nc/4.0/legalcode>



How to cite this article:
 Rawal G, Kumar R, Yadav S, Sujana R. Air Ambulance Inter-Hospital ECMO Retrieval of H1N1 Associated ARDS Patient First of Its Kind Case Reported in India. *Int. J. Life Sci. Scienti. Res.*, 2018; 4(2): 1649-1651. DOI:10.21276/ijlssr.2018.4.2.5
Source of Financial Support: Nil, **Conflict of interest:** Nil